



PRESENTING CLINICAL SIGNS

History: New grade III/VI murmur. Asymptomatic.

DATE

2/21/23

ECHOCARDIOGRAPHIC FINDINGS

2D, M-mode, and Doppler study.

PERFORMED BY:

Shari Reffi, CVT

INTERPRETED BY

Keith Blass, DVM,
MS, DACVIM
(Cardiology)

Left atrial size is normal. The mitral valve leaflets are thickened and exhibit systolic prolapse. A mild to moderate jet of eccentric mitral regurgitation is present. Left ventricular dimensions are normal. Left ventricular systolic function is hyperdynamic. The aorta and aortic valve are normal. Right atrial and right ventricular dimensions are normal. The tricuspid valve leaflets are mildly thickened, and a mild jet of tricuspid regurgitation is present. TR velocity does not suggest the presence of pulmonary hypertension. The pulmonary artery and pulmonic appear normal, though trace pulmonic insufficiency is present. No shunting lesions are visualized. No pericardial effusion or cardiac masses are seen.

PATIENT

Sweet Welsh

LA - 36.3 mm
LVIDd - 33.5 mm
LVIDs - 18.1 mm
FS - 46%
RA - 28.4 mm
LVOT - 1.48 m/s
RVOT - 1.00 m/s
TR - 2.27 m/s

SPECIES

Canine

ASSESSMENT/RECOMMENDATIONS

Degenerative mitral and tricuspid valve disease

BREED

Border Collie

This examination demonstrates regurgitation of blood across Sweet's mitral and tricuspid valves resulting from degenerative valve disease. The hemodynamic effects of each of the regurgitations appear to be mild, as Sweet does not have secondary dilation of any of her cardiac chambers. As such, Sweet's valvular diseases appear to be well-compensated, and her current risk for the development of clinical signs secondary to them, such as coughing, exercise intolerance, syncope, labored breathing, and abdominal distension, appears to be low.

SEX

No therapy is recommended at this stage of Sweet's valvular diseases.

F

A recheck echocardiogram is recommended in ~6 months to monitor for disease progression.

AGE

11 y

WEIGHT

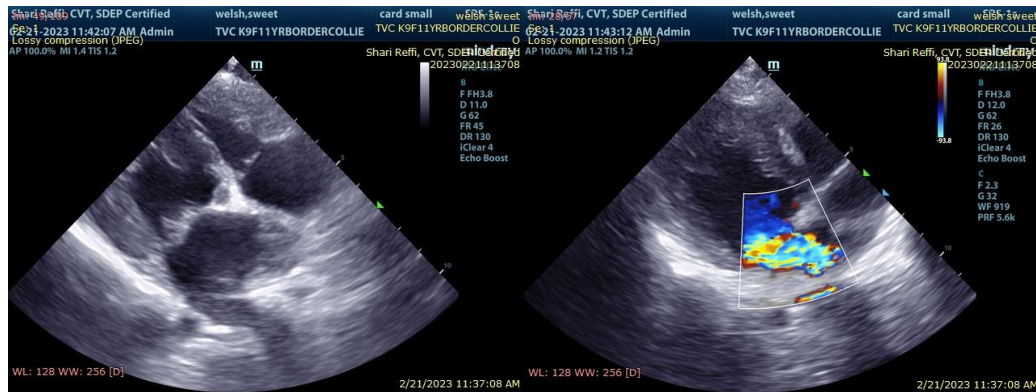
40 lb

HOSPITAL NAME

Tranquility VC

REFERRING VET

Dr. Christensen





DATE

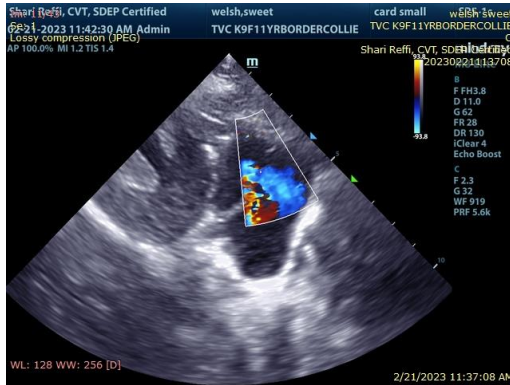
2/21/23

PERFORMED BY:

Shari Reffi, CVT

INTERPRETED BY

Keith Blass, DVM,
MS, DACVIM
(Cardiology)



The information and recommendations provided are based on the images presented by the referring veterinarian. No evaluation can be communicated regarding pathology that was not visible in the image/video clips provided.

Thank you for this referral. If the clinical or image interpretation does not parallel your findings or if I can be of any further assistance please contact me.

PATIENT

Sweet Welsh

Keith Blass, DVM, MS, DACVIM (Cardiology)
KeithBlass@gmail.com
631-804-5754

SPECIES

Canine

BREED

Border Collie

SEX

F

AGE

11 y

WEIGHT

40 lb

HOSPITAL NAME

Tranquility VC

REFERRING VET

Dr. Christensen